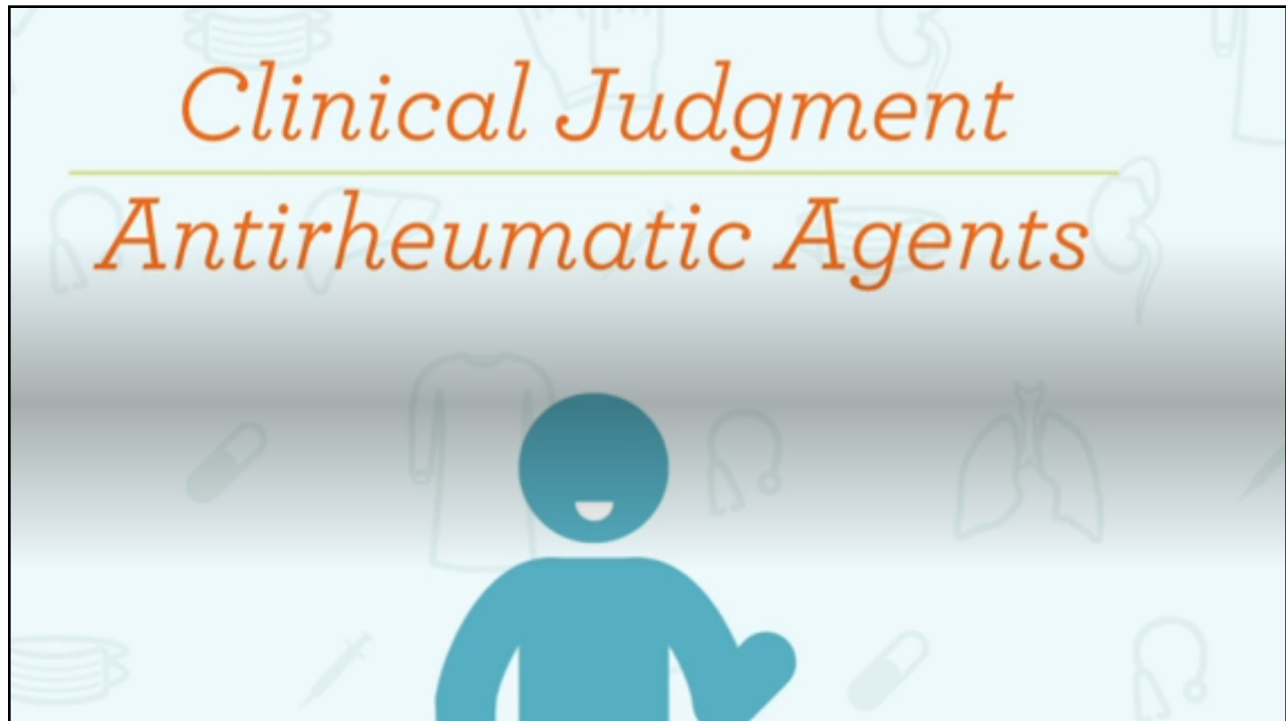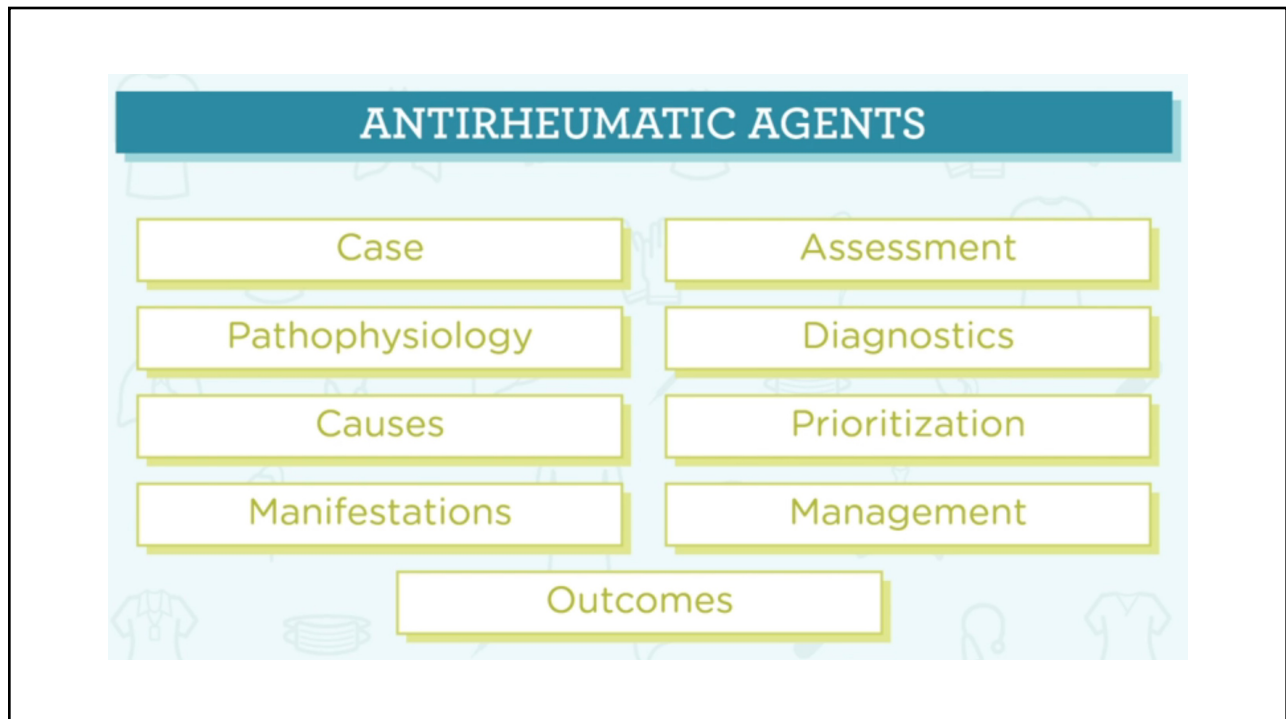



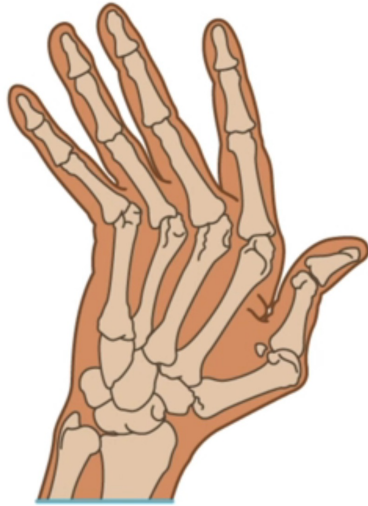
1



2


ANTIRHEUMATIC AGENTS



- Chronic
- Autoimmune disease
- Causes inflammation of the joints

3

CASE



Josie

AGE 31 years


DIAGNOSIS Rheumatoid Arthritis

AGE Methotrexate 7.5 mg PO weekly

! Worsening symptoms

4

CASE



Josie

AGE 31 years

DIAGNOSIS Rheumatoid Arthritis

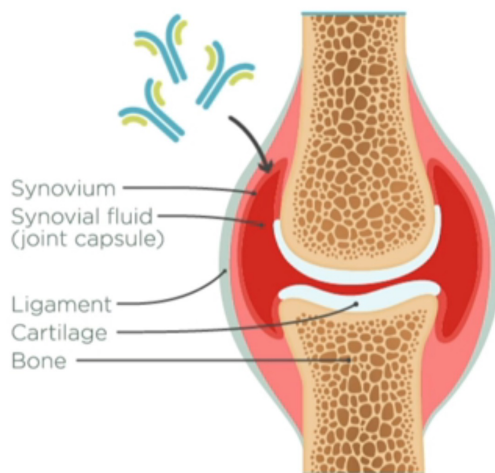
AGE Methotrexate 7.5 mg PO weekly

- ! Worsening symptoms
- ! Deformities in hands and wrists
- ! Increased difficulty ambulating

Inpatient care →

5

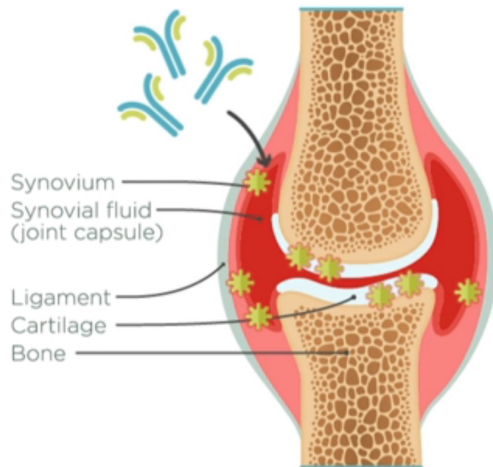
PATHOPHYSIOLOGY



- Mutated antibodies attack healthy tissue, especially synovium

6

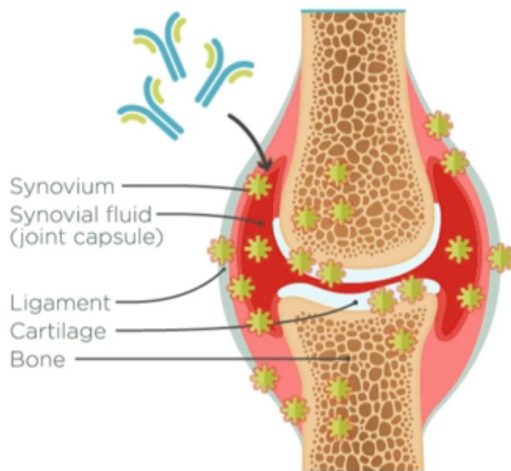
PATHOPHYSIOLOGY



- Mutated antibodies attack healthy tissue, especially synovium
- Affects articular cartilage, joint capsule, ligaments, and tendons

7

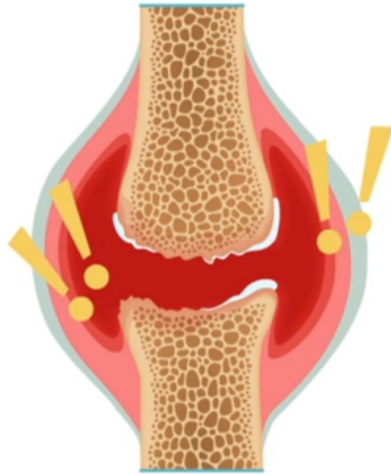
PATHOPHYSIOLOGY



- Mutated antibodies attack healthy tissue, especially synovium
- Affects articular cartilage, joint capsule, ligaments, and tendons
- Loss of bone density causes secondary osteoporosis

8


PATHOPHYSIOLOGY



- Mutated antibodies attack healthy tissue, especially synovium
- Affects articular cartilage, joint capsule, ligaments, and tendons
- Loss of bone density causes secondary osteoporosis
- Inflammation causes pain and stiffness
- Can prevent permanent joint deformities

9

CAUSES



Risk factors


- Young to middle-age females
- Infectious organisms
- Physical and emotional stress

10

MANIFESTATIONS

Early

- Upper extremity inflammation
- Generalized weakness
- Fatigue
- Anorexia
- Weight loss
- Low-grade fever



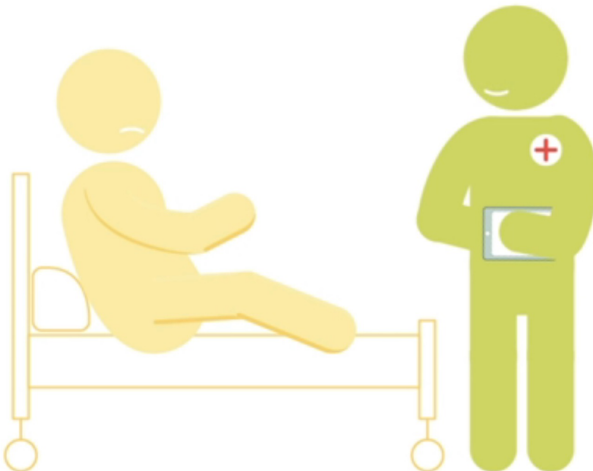
Advanced

- Painful joints
- Morning stiffness
- Muscle atrophy
- Joint deformities
- Effusions

! RA is no longer controlled

11

ASSESSMENT




- Vital signs within normal limits
- Low-grade fever 100°F
- Hands and wrists deformed
- Pain level 6/10
- Increasing weakness and fatigue
- No nodules or edema palpated
- Dry mouth and gritty eyes

! Symptoms of Sjogren's syndrome

12

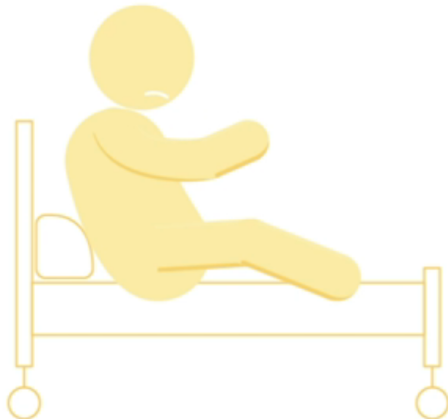DIAGNOSTICS



First tests to order		Diagnostic markers & results	
VITAL SIGNS	BP: 128/78 mm Hg HR: 82/min Sat: 97% Temp: 37.8 C RR: 20/min	CBC	WBC: 5,000 (normal) Hemoglobin: 10 (low) Hematocrit: 32% (low) Impression: mild anemia
BLOOD CULTURE	After 24 hr: negative		
ESR	60 mm/hr (elevated)	<i>indicative of inflammation</i>	
CRP	11 mg/L (elevated)	<i>indicative of inflammation</i>	
RF	Positive	<i>indicative of RA or other connective tissue diseases</i>	
ANA	Positive	<i>indicative of RA or other autoimmune conditions</i>	
ANTI-CCP	Positive	<i>indicative of RA</i>	

13

PRIORITIZATION



Priorities

- Treat Josie's worsening symptoms.
- Prevent further progression of RA.

14

MANAGEMENT

Nursing interventions

- Assess vital signs and pain every 4 hr.
- Administer NSAIDs every 6 hr for pain.
- Administer DMARDs.
- Monitor liver function test.
- Observe for jaundice or clay-colored stools.
- Give etanercept.
- Self-administer prednisone and report site reaction.
- Monitor for complications of steroids.
 - Hyperglycemia
 - Fluid and electrolyte imbalances
 - Hypertension
 - Osteoporosis
 - Glaucoma
- Support ADLs.
- Offer a warm shower.
- Educate about preventing infections.



15

OUTCOMES



Josie

- Physical therapy
- Continue new medication regimen
- Decreased pain and improved mobility
- No neutropenia or hepatotoxicity

! Elevated glucose of 276 mg/dL

! Taught to check her blood glucose

Discharged to home →

16